

Evaluation of teratogenicity of anti-osteoarthritic drugs on development of offspring of albino rats during pregnancy and lactation

Abd El Wahab El Ghareeb; Hamida Hamdi; Salwa Farouk and Esraa Khaled

Abstract—The present study aimed to evaluate the teratogenic effects of the anti-osteoarthritic drug (Genuphil) administered daily orally to the pregnant rats and nursing rats. The pregnant rats were treated during gestation and lactation with doses of 120 and 240 mg/kg. The animals were sacrificed at the end of gestation and during lactation. Fetuses were removed from the uterus and evaluated for mortality rate, growth parameters, morphological and skeletal malformation as well as histological study of liver, kidney and brain. Results showed decreased weight gain, fetal growth retardation during gestation and lactation was dose dependent. Hematomas and anomalies of limbs were detected morphologically in the fetuses of the treated groups. Fetal skeletal abnormalities included skeletal defects in hind and fore limbs, shortness of the terminal ribs, bent and wavy ribs. Histopathological studies of pregnant rats and their fetuses during gestation and lactation revealed Few inflammatory cells infiltration in the portal area as well as in between the fatty changed hepatocytes with dilatation in the portal vein, Brown pigmented material in the periphery of the dilated central veins, oedema, congestion in the portal vein, Granular and swelling degenerations in the hepatocytes in the liver. Degenerative change, swelling, Coagulation necrosis, Swelling degeneration in the lining epithelium of the tubules, swelling of the glomeruli in the lining endothelium of the tufts and focal haemorrhage in between the degenerated tubules were observed in kidney of the treated groups while vacuolization and degeneration in the cerebrum were observed in the brain following Genuphil administration.

Key words — Teratogenicity, Genuphil, Gestation, Lactation.

1 INTRODUCTION

TERATOLOGY is the study of abnormal prenatal development and congenital malformations induced by exogenous chemical or physical agents continues to be a burgeoning area of medical research in the quest for the eradication of preventable birth defects. Identification of agents with teratogenic potential from the plethora of drugs and chemicals that human beings come into contact with in their everyday environment is crucial. Although, only 10 % of congenital anomalies are thought to be caused by teratogens representing roughly one in every thousand live births, they compromise the quality of life for millions of individuals worldwide and cost billions of dollars in health care every year (Brent, 1995).

Osteoarthritis is essentially a debilitating disease characterized by a gradual loss of articular cartilage in synovial joints that causes painful impairment. Functional limitation gradually occurs as a result of joint stiffness and progressive loss of joint motion owing to deformities (loss of the cartilage surface and side growth of osteo-phytes) accompanied by inflammation of the synovial membrane. The clinical symptoms of OA are pain and functional impairment that includes joint stiffness and dysfunction. In 80 % of patients with OA, movement is limited to some degree. This leads to impaired performance in the work place, and 25% of patients cannot perform their main activities of daily life, which often leads to social isolation and depression (Kean et al., 2004).

Current treatments for the management of OA are not curative and do not reverse the degenerative process of OA. Non-steroidal anti-inflammatory drugs (NSAIDs) have been used for the past several years in the treatment of OA, but their therapeutic effects remain unsatisfactory. Accordingly, the development of novel drugs from natural sources, which can

be safely used in prolonged treatment of OA and provide cartilage protection, is needed (Schnitauer et al., 2004).

Genuphil is the ultimate joint care formula that contains the essential components responsible for maintaining the normal structure of the articular cartilage and synovial fluid of the joints & reduces the pain and inflammation associated with these conditions. Genuphil contains glucosamine and chondroitin, the two well-known ingredients for their synergistic effect in restoring the normal balance of cartilage metabolism where they stimulate the cartilage anabolic process and inhibit the degradative enzymes thus decreasing the rate of cartilage catabolism. Genuphil contains also, Methyl Sulfonyl Methane (MSM) the natural source of organic sulfur that is essential for proteoglycans synthesis, a process that is mandatory for final assembly of the cartilage. Sulfur also, through forming the disulfide bonds is needed for the collagen synthesis where collagen is the main structural protein of the soft tissue such as cartilage, tendon, ligaments and muscles. This Study is designed to evaluate the teratogenicity of anti-osteoarthritic drug (Genuphil) on development of offspring of albino rats when administered during pregnancy and lactation.

2 MATERIALS AND METHODS

2.1 Experimental animals

The present experimental study is carried out on the white albino rat (*Rattus norvegicus*). The standard guidelines of the Institutional Animal Care and Use Committee (IACUC) were used in handling animals. Females of 11-13 weeks old were selected for the present study and the vaginal smears were

prepared every morning and examined under light microscope (according to the method of Snell (1956) for 5 days to select the female with regular estrus. Two females with regular estrus cycle were selected in the pro-estrus stage and caged together with one male overnight under controlled environmental conditions of temperature, humidity and light. The first day of gestation was determined by the presence sperms in the vaginal smear (McClain & Becker, 1975).

A daily record of the weight of the pregnant females was made throughout the whole gestation period. The percentages of abortion were calculated in each group; abortion was determined by the presence of blood drops in the weight of the pregnant females.

2.2 Experimental strategy

Genuphil Drug was manufactured by Eva pharma for pharmaceuticals & medical appliances, Egypt.

2.3 Experimental design

The Route of administration was Oral. The time of administration was scheduled from the 5th day of gestation, daily during both gestation and lactation.

2.4 Experimental groups

During gestation

Group A: Control rats received distilled water from 5th day of gestation to 19th day of gestation.

Group B: Rats treated with 120 mg/kg of Genuphil from 5th day of gestation to 19th day of gestation.

Group C: Rats treated with 240 mg/kg of Genuphil from 5th day of gestation to 19th day of gestation.

During lactation

Control group: Control rats received distilled water from 5th day of gestation to 6th, 13th and 20th day of lactation.

Group administrated 120 mg/kg: Rats treated with 120 mg/kg of Genuphil from 5th day of gestation to 6th, 13th and 20th day of lactation.

Group administrated 240 mg/kg: Rats treated with 240 mg/kg of Genuphil from 5th day of gestation to 6th, 13th and 20th day of lactation.

2.5 Developmental observations

At the 20th day of gestation, all pregnant rats groups (A to C) were sacrificed and total implantation sites, fetal mortality rate (resorbed or still birth) and living fetuses were recorded. Fetal body weight, body length, tail length and external malformation were recorded. Head, neck and limbs were examined. The neonates were sacrificed at the 7th, 14th and 21th day of lactation, respectively. Fetal body weight, body length and tail length were recorded.

2.6 Skeletal examination

Fetuses were preserved in 95 % ethyl alcohol and stained with double staining of fetal skeletons for cartilage (Alcian blue) and bone (Alizarin red) according to the method described by Inouye (1976).

2.7 Histological examination

Autopsy samples were taken from liver, kidney and brain of

mother rats and fetuses in different groups at the 20th day of gestation and from neonates at the 7th, 14th and 21th day of lactation. They were fixed in 10 % formal saline for 24 h. washing by tap water, and then serial dilutions of alcohol (methyl, ethyl and absolute ethyl) were used for dehydration. Specimens were cleared in xylene and embedded in paraffin at 56 degree in hot air oven for twenty four hours. Paraffin bees wax tissue blocks were prepared for sectioning at 4 microns thickness by sledge microtome. The obtained tissue sections were collected on glass slides, deparaffinized, stained by hematoxylin & eosin stain for routine examination then examination was done through the light electric microscope (Banchroft et al., 1996).

2.8 Statistical analysis

Statistical analysis was performed using the Analysis Of Variance (ANOVA) and Duncan's multiple Range Test to determine differences between treatments, means at significance level of 0.05. Standard errors of treatment means were also estimated. All statistics were carried out using Statistical Analysis Systems (SAS) program (SAS, 2009).

3 RESULTS

3.1 Morphological studies during gestation period

Change in body weight gain

The maternal body weight was followed all over the period of gestation for the Control and experimental groups. The average maternal body weight was recorded for the control and experimental groups on the 5th and the 20th day of gestation (Table 1 and Fig. 1). The weight gain of pregnant rats treated with 120 mg/kg & 240 mg/kg of Genuphil from 5th to 19th day of gestation was decreased than that of the control group but not significant ($P > 0.05$).

Table 1. Changes in weight gain of pregnant rats during gestation period.

Groups	Average Wt. at the 5 th day of gestation	Average Wt. at the 20 th day of gestation	Average increase in weight
Control	169.91	223.5	53.58 ± 5.54 a
120 mg/kg	187.65	235.98	48.32 ± 3.32 a
240 mg/kg	183.95	222.95	39.00 ± 6.82 a

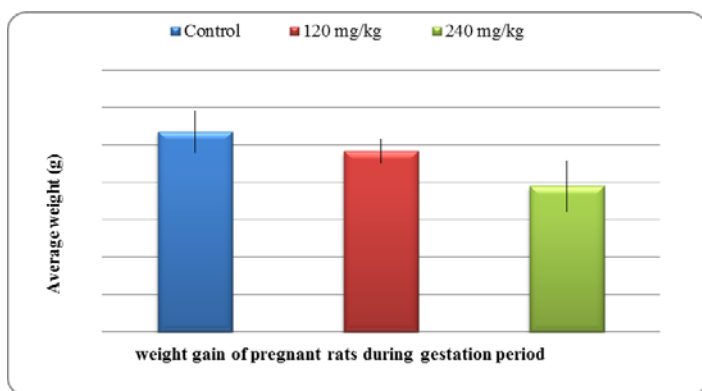


Fig. 1. Histogram for change in weight gain of pregnant albino rats during gestation period.

3.2 Effect of anti-osteoarthritic drug (Genuphil) on uterus

The control uterus obtained from pregnant rats on day 20th of gestation showed normal distribution of fetuses between the two horns (Fig. 2A). The uterus of pregnant rats treated with 120 mg/kg & 240 mg/kg of Genuphil showed asymmetrical distribution of fetuses in the two uteri horns (Fig. 2B&E). Table (2) showed that all 10th uteri of control group did not exhibit any resorption while one uterus of examined uteri in group B which treated with 120 mg/kg Genuphil from 5th to 19th day of gestation exhibits both partial and complete resorption (Fig. 2C). In group C which treated with 240 mg/kg Genuphil from 5th to 19th day of gestation, five of the examined uteri exhibit complete resorption while no partial resorption occurred in this group (Fig. 2D).

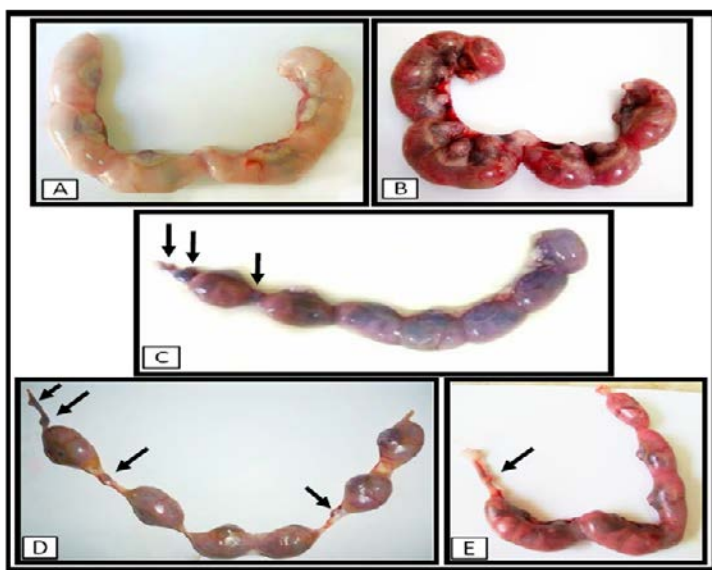


Fig. 2. Photographs for uteri of pregnant albino rats at the 20th day of gestation, A; control, B; 120 mg/kg of Genuphil, C; 120 mg/kg of Genuphil, D; 240 mg/kg of Genuphil, E; 240 mg/kg of Genuphil.

Table 2. Effect of Genuphil on uteri of pregnant rats at the 20th day of gestation.

Groups	Total no. of Uteri	No. of uteri without resorption	No. of uteri with partial resorption	No. of uteri with complete resorption
Control	10	10	0	0
120 mg/kg	16	15	1	1
240 mg/kg	18	13	0	5

3.3 Average weight of placenta

The effect of Genuphil on the weight of placenta of pregnant rats was recorded in Table (3). There was a high significant ($P < 0.01$) decrease in the average weight of placenta of pregnant rats treated with 120 mg/kg Genuphil from 5th to 19th day of gestation as compared to control. The average weight of placenta of pregnant rats treated with 240 mg/kg Genuphil from 5th to 19th day of gestation was highly significantly ($P < 0.01$) decreased as compared to control (Fig. 3).

3.4 Effect of Genuphil on fetuses

Growth retardation

The morphological examination of the fetuses showed that Genuphil caused growth retardation represented by decrease in fetal body weight, body length and tail length (Table 3 and Fig. 3).

The body weight of fetuses at the 20th day of gestation

The average body weight of fetuses maternally treated with 120 & 240 mg/kg of Genuphil from 5th to 19th day of gestation was significantly ($P < 0.05$) decreased as compared to control group.

The body length of fetuses at the 20th day of gestation

The average body length of fetuses maternally treated with 120 & 240 mg/kg of Genuphil from 5th to 19th day of gestation was decreased than that of the control group but not significant ($P > 0.05$).

The tail length of fetuses at the 20th day of gestation

The average tail length of fetuses maternally treated with 120 & 240 mg/kg of Genuphil from 5th to 19th day of gestation was highly significantly ($P < 0.01$) decreased than those of the control group.

3.5 Fetal Mortality

Total mortality rate included resorbed fetuses and dead fetuses at the 20th day of gestation were recorded for control and experimental groups in Table (4). Total mortality rate of fetuses maternally treated with 120 mg/kg of Genuphil from 5th to 19th day of gestation was 9.42% compared to control while in group C, total mortality rate of fetuses maternally treated with 240 mg/kg of Genuphil from 5th to 19th day of gestation was 9.66%.

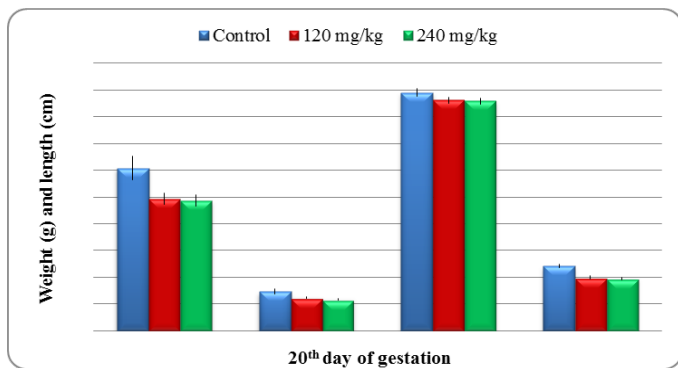


Fig. 3. A histogram showing effect of anti-osteoarthritic drug (Genuphil) on placenta weight, fetuses body weight, length and tail length at the 20th day of gestation.

Table 3. Fetus weight, placenta weight, fetus length and tail length at the 20th day of gestation. Data are represented as mean \pm standard error. Means with the same letter are not significantly different. F-probability expresses the effect between groups, where $P < 0.05$ is significant and $P < 0.01$ is highly significant.

Groups	Average body wt. of fetuses (FWt)	Average weight of placenta (PWt)	Average body length of fetuses (FL)	Average tail length of fetuses (TL)
Control	a 3.03 \pm 0.223	a 0.73 \pm 0.04	a 4.45 \pm 0.078	a 1.20 \pm 0.03
120 mg/kg	b 2.46 \pm 0.10	b 0.62 \pm 0.02	a 4.30 \pm 0.06	b 0.99 \pm 0.02
240mg/kg	b 2.43 \pm 0.10	b 0.58 \pm 0.02	a 4.29 \pm 0.05	b 0.97 \pm 0.02

Table 4. Effect of Genuphil on fetal mortality at the 20th day of gestation.

Parameters	Groups		
	Control	120 mg/kg	240 mg/kg
Total no. of sacrificed rat	10	16	18
No. of Implantation sites	67	138	145
No. of fetuses per litter	6.7	8.63	8.06
No. of live fetuses	67	125	131
	100	90.58	90.35
No. of resorbed fetuses	0	3	12
	0	2.17	8.28
No. of dead fetuses	0	8+2	2
	0	7.25	1.38
Total mortality rate	0	13	14
	0	9.42	9.66

3.6 Morphological malformation

Rat fetuses of the control group on the 20th day of gestation

had formed their normal C-shaped body with normal extremities. The upper and lower extremities were in their normal locations. No abnormal limbs were noted in the control group (Figs. 4A & 5A). Pregnant rats in the treated groups were carrying fetuses, with hematoma on their extremities as shown in Table (5) and (Figs. 8B, 8C, 9E). Other sites of hematoma observed at tail, abdomen, back, neck and head (Figs. 4(B, C, D), 5B & 8A). Hematoma could be detected in the same fetuses in different sites (Fig. 8B). No hematoma occurred in control group while in group B (120 mg/kg), the percentage of hematoma was 47.10%. In group C (240 mg/kg), the percentage of hematoma was 28.97 %.

Table 5. Effect of Genuphil on the percentage of hematoma in fetuses at the 20th day of gestation.

Groups	No. of examined fetuses	No. of hematoma	Percentage of hematoma
Control	67	0	0 %
120 mg/kg	138	65	47.10 %
240 mg/kg	145	42	28.97 %

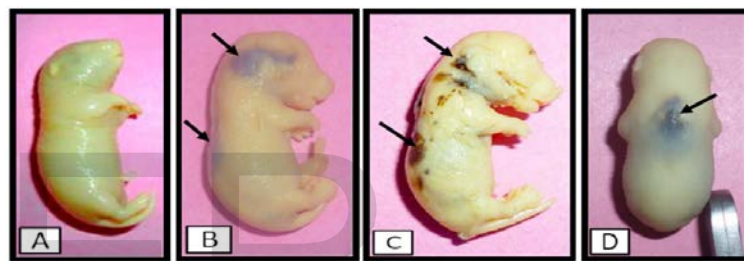


Fig. 4. Photographs of fetuses at the 20th day of gestation. A: Control fetus, B: Fetus maternally treated with 120 mg/kg of Genuphil, C: treated with 120 mg/kg of Genuphil, D: treated with 240 mg/kg of Genuphil.

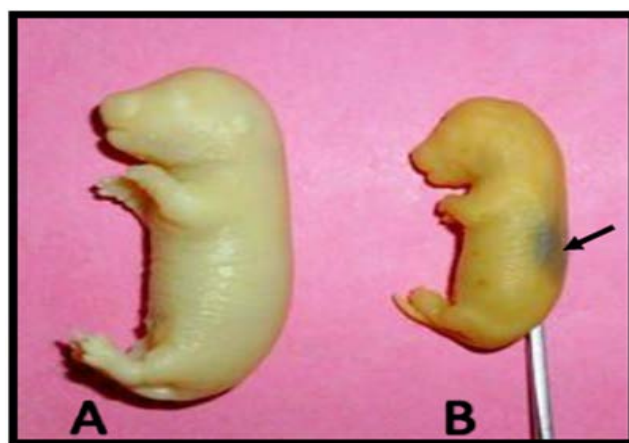


Fig. 5. A Photograph of two fetuses at the 20th day of gestation. A Control fetus, B: Fetus maternally treated with 120 mg/kg of Genuphil showing hematoma at the back and growth retardation.

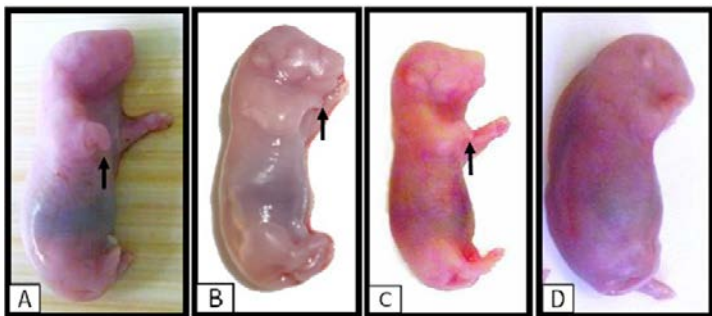


Fig. 6. Photographs of fetuses at the 20th day of gestation. A,B: Fetuses maternally treated with 120 mg/kg of Genuphil, C, D: Fetus maternally treated with 240 mg/kg of Genuphil.

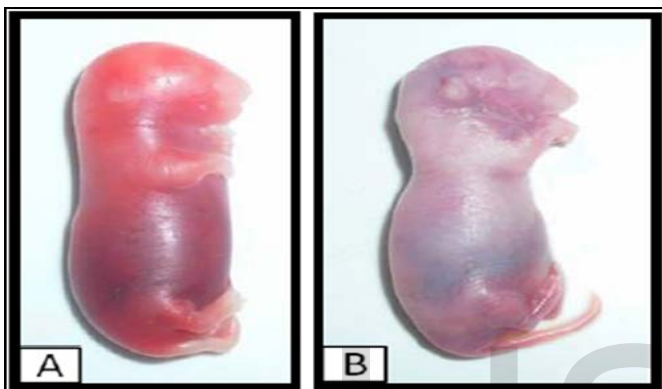


Fig. 7. Photographs of two fetuses at the 20th day of gestation treated with 240 mg/kg of Genuphil.

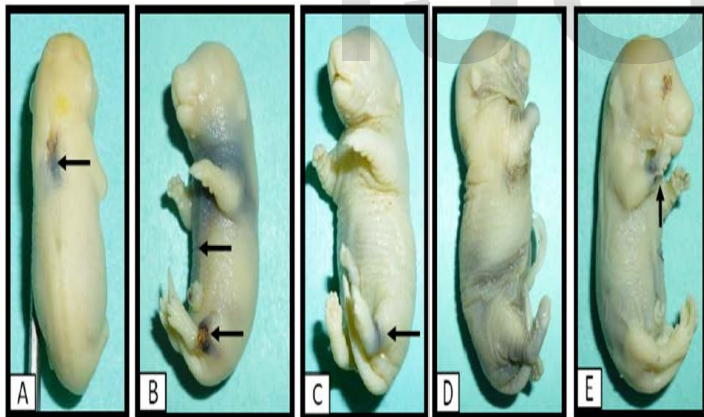


Fig. 8. A Photograph of fetuses at the 20th day of gestation treated with 120 mg/kg of Genuphil.

In treated groups, multiple fetuses had obvious abnormalities of their limbs and body. In group B which treated with 120 mg/kg from 5th to 19th day of gestation, some fetuses had abnormal increase in normal number of fingers of the left fore limb, short limbs and contraction of their fore limbs (Figs. 6A&B, 8E). Disintegration of two fetuses occurs in group B (120 mg/kg) as shown in Figure (9A&B). In group C which treated with 240 mg/kg from 5th to 19th day of gestation, some fetuses had an abnormal body shape, short limbs and contraction of their fore limbs (Figs. 6C, 7 A&B). Also, disintegration and breaking down of two fetuses occur in group C (Fig. 9

C&D).

The percentage of shortness of limbs was 14.94% in group B (120 mg/kg) and was 12.41% in group C with dose 240 mg/kg. Absence of limbs was 0.73% in group B (120 mg/kg), as shown in table 6. Absence of limbs was 0.69% in group C (240 mg/kg) (Table 6 and Fig. 9E). Brachydactyly was manifested by having abnormal short digits; this anomaly was 0.73% in group B (120 mg/kg), as shown in Table (6).

Table 6. Effect of Genuphil on external anomalies in the fetuses at the 20th day of gestation.

Groups	No. of fetuses examined	Anomalies of limbs					
		Shortness of limbs		Absence of limbs		Shortness of digits	
		No.	%	No.	%	No.	%
Control	67	-	-	-	-	-	-
120 mg/kg	183	20	14.94	1	0.73	1	0.73
240 mg/kg	145	18	12.41	1	0.69	-	-

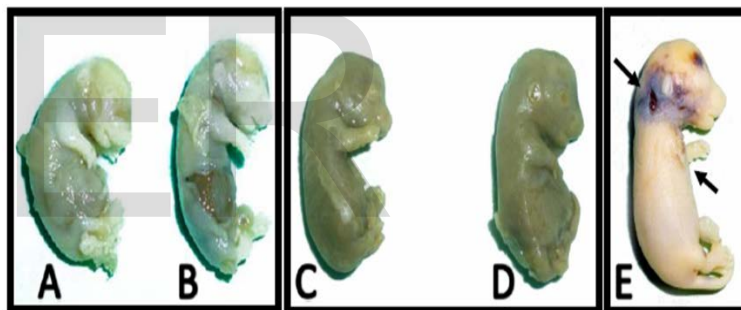


Fig. 9. Photographs of fetuses at the 20th day of gestation. A, B: treated with 120 mg/kg of Genuphil, C,D: treated with 240 mg/kg of Genuphil, E: Fetus maternally treated with 240 mg/kg of Genuphil.

3.7 Skeletal anomalies

For more detailed evaluation of cartilage and ossified bone in teratogenicity studies, the double-staining technique with Alizarin red S and Alcian blue was applied to observe skeletal abnormalities in fetuses obtained on gestational day 20. The bony components were stained red with alizarin red S while the cartilages stained with alcian blue.

Control group

At the 20th day of gestation, the cleared cartilage and bone preparations of control rat fetuses have designated that in all parts of the axial skeleton skull, vertebrae and ribs as well as appendicular skeleton comprising the fore and hind limbs, pectoral and pelvic girdles, both chondrification and ossification processes have been obviously completed. These cases are well illustrated in Figure (10A) which are displaying the developed cartilage and bone in the different parts of skeleton of these fetuses. The cartilaginous parts of the skull included the

nasal region. Cranium of control fetuses of rat received distilled water from 5th day of gestation to 19th day of gestation showing well ossification. Maxilla, mandible, frontal, parietal and occipital are completely ossified and stained red. In the vertebral column, the proximal ends of the transverse processes and vertebral arches have cartilaginous ends. Ribs of control fetuses, at the 20th day of gestation, acquired a normal set of 13 pairs of ribs; each of which consists of a cartilaginous part (the sternal portion of ribs) and a fully ossified part (the vertebral portion of ribs) as demonstrated in Figs. (10A&11A). The ribs of control fetus of rat were well ossified. The body and arch of all the vertebrae were ossified. There were already red-stained areas in the distal (forepaw phalanx), proximal phalanges and metacarpal bones, indicating the ossification of many areas of fetal hand/ forelimb bones. In the hind limb of control fetus, metatarsal bones, proximal and distal phalanges were ossified (Fig. 10A&11A).

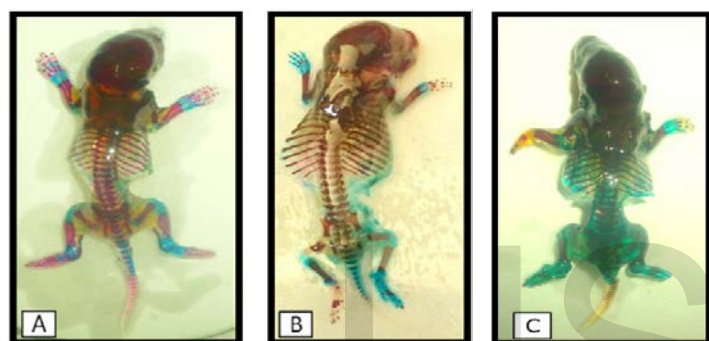


Fig. 10. Photographs of skeletal system of rat fetuses at the 20th day of gestation and stained with Alizarin red - S and Alcian blue. A; Skeletal system of control fetus showing well ossified skeletal elements, B; treated with 120 mg/kg of Genuphil, E ; treated with 240 mg/kg of Genuphil.

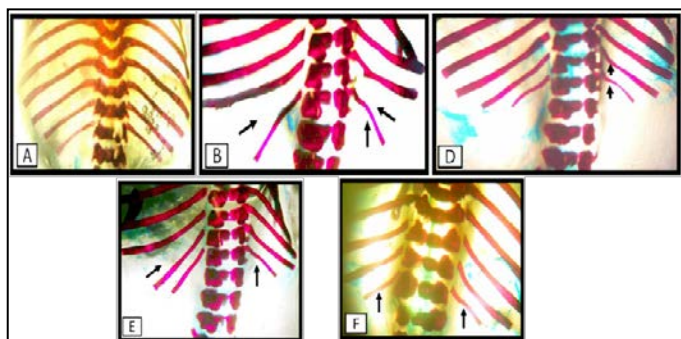


Fig. 11. Photographs of ribs of rat fetus at the 20th day of gestation stained with Alizarin red - S and Alcian blue (Bones in red and cartilages in blue), A; The ribs of control, B; Wavy, bent ribs and costal separation anomaly induced by maternal treatment with 120 mg/kg of Genuphil, C; Wavy and bent ribs induced by treatment with 240 mg/kg of Genuphil, D; Columna vertebralis of rat fetus maternally treated with 240 mg/kg of Genuphil showing wavy ribs and costal separation anomaly, E; Columna vertebralis of rat fetus maternally treated with 240 mg/kg of Genuphil.

Treated groups

On the other hand, fetuses maternally treated with 120 mg/kg

of Genuphil from 5th to 19th day of gestation showed some skeletal abnormalities (Fig. 10B). Wavy and bent ribs (11th to 13th) were seen in some fetuses (Fig. 11B). Costal separation anomaly was observed in some fetuses (Fig. 11B). The major skeletal defects were observed mainly in hind and fore limbs. Hand/forelimb abnormal shape (claw hand), bent distal part of fore limb digit bones and fused forepaw phalanx was seen in one of the fetuses. Curvature was also seen in fore limb bones of some fetuses. Fusion of 3rd and 4th metatarsal bones (fused metatarsal-metatarsal) was observed in the hind limb (Fig. 12B).

Some skeletal malformations were observed in fetuses from pregnant rats treated with 240 mg/kg Genuphil from 5th to 19th day of gestation (Fig. 10E). Shortness of 13th rib, wavy and bent ribs was seen in some fetuses of this group (Figs.10E, 11C, D& E). Also, Costal separation anomaly was seen in some fetuses of this group (Fig. 11E).

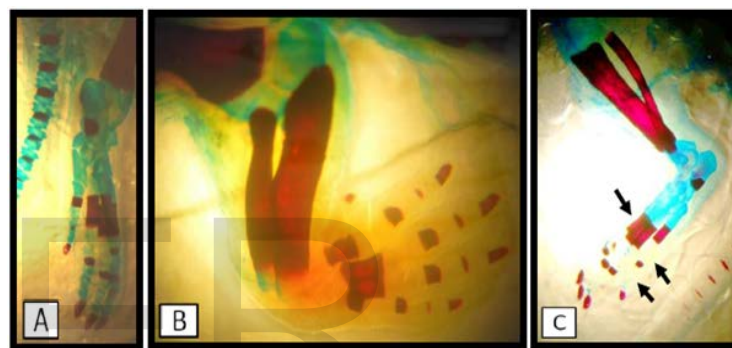


Fig. 12. A Photograph of hind limb of rat fetus at the 20th day of gestation stained with Alizarin red - S and Alcian blue (Bones in red and cartilages in blue), A; Normal hind limb of control fetus, B; Fusion of 3rd and 4th metatarsal bones (fused metatarsal-metatarsal) in hind limb of fetus maternally treated with 120 mg/kg of Genuphil, C; Fusion of 2nd, 3rd and 4th metatarsal bones and absence of blue stained areas of cartilage between phalanges in hind limb of fetus maternally treated with 240 mg/kg of Genuphil.

3.8 Histopathological findings on liver, brain and kidney

In the liver of control, there was no histopathological alteration as recorded in (Fig. 13A). However, the Kidney, there was no histopathological alteration as recorded in (Fig.15A&B).

The Liver of rats group of administered 120 mg/kg BW Genuphil, Brown pigmented material was detected in the periphery of the dilated central veins (Fig.13B&C). There was activation and proliferation of the haemobiotic cells in between the degenerated hepatocytes (Fig. 13D&E). Whenever in the kidney, the lining epithelium of the tubules showed disfiguration associated with tubular cystic dilatation (Fig. 15C&D).

The liver of rats Group administered 240 mg/kg BW Genuphil, dilatation was noticed in the central vein (Fig. 13F), associated with degeneration in the hepatocytes (Fig. 14A). Focal haemorrhage was detected in the hepatic parenchyma (Fig. 14B) associated with appearance of megakaryblasts (Fig.

14C). The kidney, Coagulation necrosis was noticed in the lining epithelium of the tubules (Fig. 15E&F).

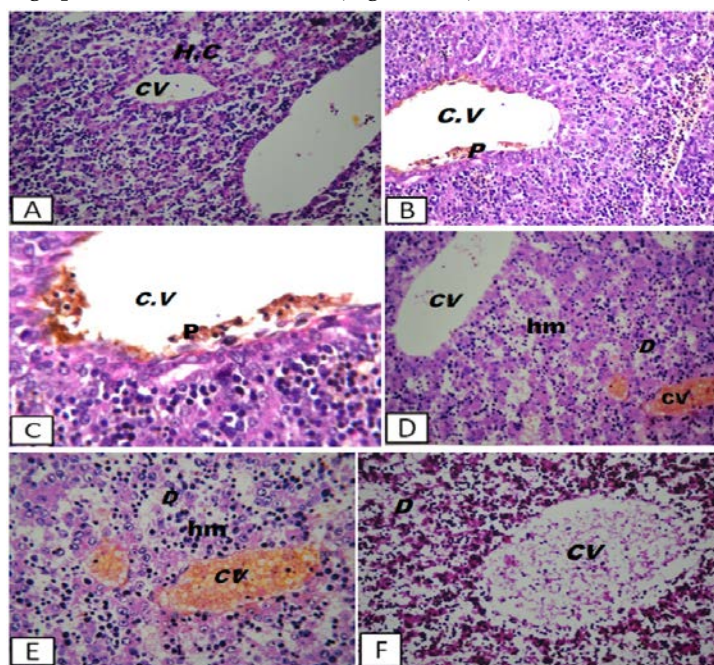


Fig. 13. Photomicrographs of a section in liver of albino rat fetuses at the 20th day of gestation. A: control, B: A section of liver of fetus maternally treated with 120 mg/kg of Genuphil H&E (x40); C: treated with 120 mg/kg of Genuphil H & E (x64); D: treated with 120 mg/kg of Genuphil H & E (x40); E: treated with 120 mg/kg of Genuphil H & E (x46); F: treated with 240 mg/kg of Genuphil H & E (x40).

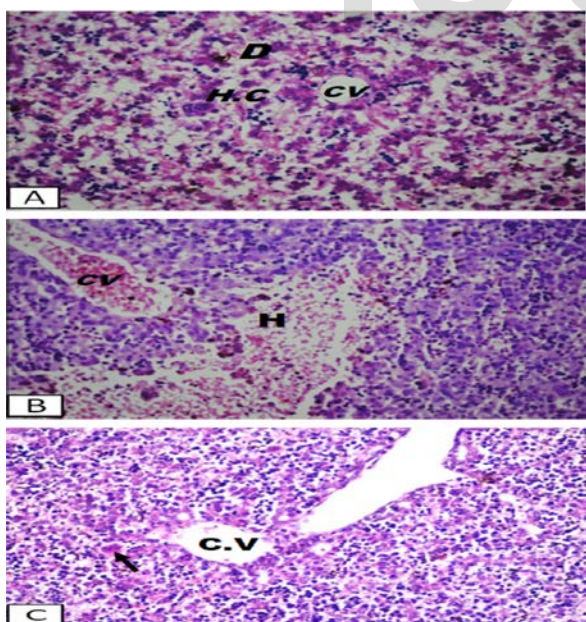


Fig. 14. Photomicrographs of a section of liver of albino rat fetuses at the 20th day of gestation A: treated with 240 mg/kg of Genuphil H & E (x40), B: treated with 240 mg/kg of Genuphil H & E (x40), C: treated with 240 mg/kg of H & E (x40).

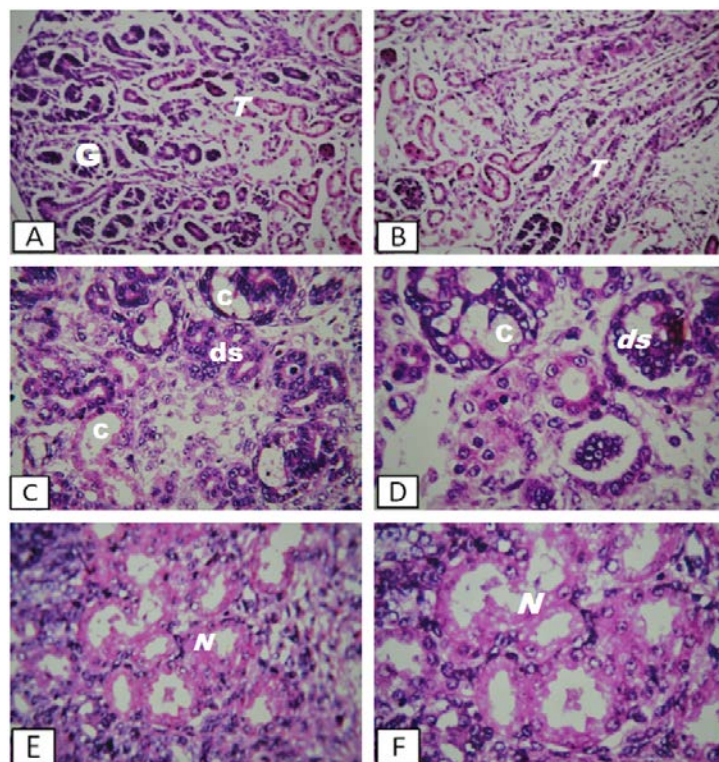


Fig. 15. Photomicrographs of a section of kidney of albino rat fetuses at the 20th day of gestation glomeruli (G) and tubules (T). A&B: control fetus H & E (x40); C &D: treated with 120 mg/kg of Genuphil H & E (x40 & x64); E: treated with 240 mg/kg of Genuphil H & E (x40); F: treated with 240 mg/kg of Genuphil H & E (x64).

3.9 Morphological studies during lactation

Effect of Genuphil on albino rat neonates

Fetal Mortality

Total mortality rate included dead neonates during lactation (from 1st day of lactation to 21th day of lactation) were recorded for control and experimental groups in Table (7). No dead neonates were found in control group while in the second group in which neonates maternally treated with 120 mg/kg Genuphil from 5th day of gestation to 6th, 13th and 20th day of lactation, number of dead neonates were 2 at first day of lactation and 4 at 2nd day of lactation. In third group (240 mg/kg), 28 dead neonates were found during lactation. In this group, 27 neonates died from 1st day of lactation to 4th day of lactation and one neonate died at 14th day of lactation. Total mortality rate of neonates maternally treated with 120 mg/kg Genuphil from 5th day of gestation to 6th, 13th and 20th day of lactation was 9.09% while in third group, total mortality rate of neonates maternally treated with 240 mg/kg Genuphil from 5th day of gestation to 6th, 13th and 20th day of lactation was 43.75% as shown in Table (7).

Table 7. Effect of Genuphil on fetal mortality During Lactation (after birth to 21th day of lactation). The data are represented as percentage (%).

Groups	Total no. of rats give birth	Total no. of neonates		No. of live neonates	No. of dead neonates		Total mortality rates	
Control	9	54	54	100%	0	0	0	0
120mg/kg	11	66	60	90.91%	6	9.09%	6	9.09%
240mg/kg	10	64	36	56.25%	28	43.75 %	28	43.75 %

Growth retardation

The morphological examination of the neonates showed that Genuphil caused growth retardation represented by decrease in body weight, body length and tail length (Tables 8, 9, 10, 11), (Figs. 16, 17, 18, 19).

The body weight of neonates at the 1st day of lactation

The average body weight of neonates maternally treated with 120 & 240 mg/kg Genuphil from 5th day of gestation to 1st day of lactation was decreased than that of the control group but not significant ($P > 0.05$).

The body length of neonates at the 1st day of lactation

The average body length of neonates maternally treated with 120 & 240 mg/kg Genuphil from 5th day of gestation to 1st day of lactation was decreased as compared to control group but not significant ($P > 0.05$).

The tail length of neonates at the 1st day of lactation

The average tail length of neonates maternally treated with 120 & 240 mg/kg Genuphil from 5th day of gestation to 1st day of lactation was decreased than that of the control group but not significant ($P > 0.05$).

The body weight of neonates at the 7th day of lactation

The average body weight of neonates maternally treated with 120 & 240 mg/kg Genuphil from 5th day of gestation to 6th day of lactation was significantly ($P < 0.05$) decreased as compared to the control group.

The body length of neonates at the 7th day of lactation

The average body length of neonates maternally treated with 120 & 240 mg/kg Genuphil from 5th day of gestation to 6th day of lactation was decreased than that of the control group but not significant ($P > 0.05$).

The tail length of neonates at the 7th day of lactation

The average tail length of neonates maternally treated with 120 & 240 mg/kg Genuphil from 5th day of gestation to 6th day of lactation was decreased than that of the control group but not significant ($P > 0.05$).

The body weight of neonates at the 14th day of lactation

The average body weight of neonates maternally treated with 120 & 240 mg/kg Genuphil from 5th day of gestation to 13th day of lactation was decreased as compared to control group but not significant ($P > 0.05$).

The body length of neonates at the 14th day of lactation

The average body length of neonates maternally treated with 120 mg/kg Genuphil from 5th day of gestation to 13th day of lactation was decreased than that of the control group but not significant ($P > 0.05$). The average body length of neonates maternally treated with 240 mg/kg Genuphil from 5th day of ges-

tation to 13th day of lactation was significantly ($P < 0.05$) decreased as compared to the control group.

The tail length of neonates at the 14th day of lactation

The average body length of neonates maternally treated with 120 mg/kg Genuphil from 5th day of gestation to 13th day of lactation was decreased than that of the control group but not significant ($P > 0.05$). The average tail length of neonates maternally treated with 240 mg/kg from 5th day of gestation to 13th day of lactation was significantly ($P < 0.05$) decreased as compared to the control group.

The body weight of neonates at the 21th day of lactation

The average body weight of neonates maternally treated with 120 & 240 mg/kg Genuphil from 5th day of gestation to 20th day of lactation was highly significantly ($P < 0.01$) decreased as compared to the control group.

The body length of neonates at the 21th day of lactation

The average body length of neonates maternally treated with 120 & 240 mg/kg Genuphil from 5th day of gestation to 20th day of lactation was highly significantly ($P < 0.01$) decreased as compared to the control group.

The tail length of neonates at the 21th day of lactation

The average tail length of neonates maternally treated with 120 mg/kg Genuphil from 5th day of gestation to 20th day of lactation was decreased than that of the control group but not significant ($P > 0.05$). The average tail length of neonates maternally treated with 240 mg/kg Genuphil from 5th day of gestation to 20th day of lactation was significantly ($P < 0.05$) decreased as compared to the control group.

Table 8. The body weight, body length and tail length of neonates at the 1st day of lactation. Data are represented as mean \pm standard error. Means with the same letter are not significantly different.

Groups	Average body wt. of neonates (FWt)	Average body length of neonates (FL)	Average tail length of neonates (TL)
Control	5.77 \pm 0.13	4.61 \pm 0.03	1.63 \pm 0.02
120 mg/kg	5.66 \pm 0.09	4.58 \pm 0.03	1.61 \pm 0.01
240 mg/kg	5.43 \pm 0.14	4.58 \pm 0.04	1.59 \pm 0.02

Table 9. The body weight, body length and tail length of neonates at the 7th day of lactation. Data are represented as mean \pm standard error. Means with the same letter are not significantly different. b significantly different from a at ($P < 0.05$).

Groups	Average body wt. of neonates (FWt)	Average body length of neonates (FL)	Average tail length of neonates (TL)
Control	9.50 \pm 0.24	6.26 \pm 0.11	2.16 \pm 0.03
120 mg/kg	8.12 \pm 0.40	5.67 \pm 0.25	2.1363636 \pm 0.0936849
240 mg/kg	7.93 \pm 0.29	5.65 \pm 0.14	2.05 \pm 0.02

Table 10. The body weight, body length and tail length of neonates at the 14th day of lactation. Data are represented as mean \pm standard error. Means with the same letter are not significantly different. b significantly different from a at ($P < 0.05$).

Groups	Average body wt. of neonates (FWt)	Average body length of neonates (FL)	Average tail length of neonates (TL)
Control	15.81 \pm 0.74	7.71 \pm 0.15	3.30 \pm 0.11
120 mg/kg	14.65 \pm 0.91	7.69 \pm 0.04	3.28 \pm 0.05
240 mg/kg	14.64 \pm 0.98	7.32 \pm 0.03	3.01 \pm 0.02

Table 11. The body weight, body length and tail length of neonates at the 21th day of lactation. Data are represented as mean \pm standard error. Means with the same letter are not significantly different.

Groups	Average body Wt. of neonates	Average body length of neonates	Average tail length of neonates
Control	35.30 \pm 3.11	11.32 \pm 0.53	5.70 \pm 0.26
120mg/kg	20.65 \pm 1.79	9.36 \pm 0.36	5.20 \pm 0.23
240mg/kg	19.30 \pm 1.69	9.33 \pm 0.02	4.44 \pm 0.01

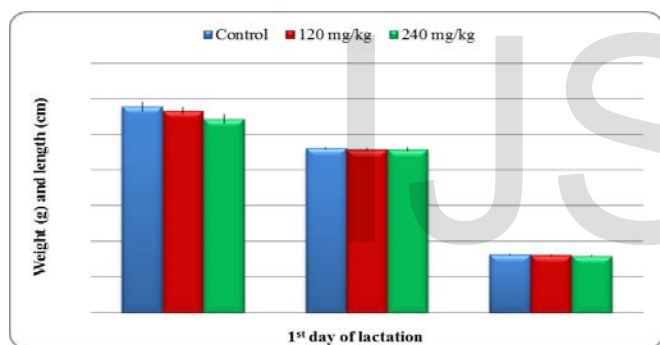


Fig. 16. A histogram showing effect of anti-osteoarthritic drug (Genuphil) on neonates body weight, length and tail length at the 1st day of lactation.

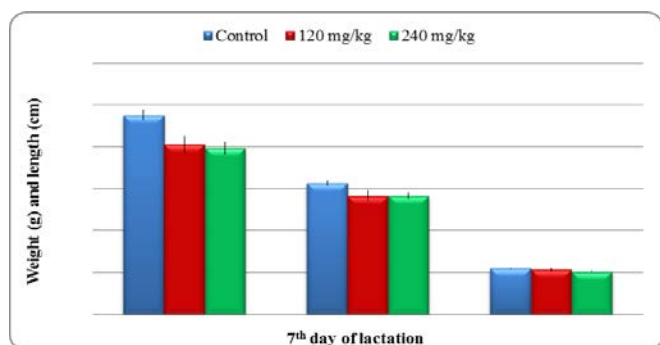


Fig. 17. A histogram showing effect of anti-osteoarthritic drug (Genuphil) on neonates body weight, length and tail length at the 7th day of lactation.

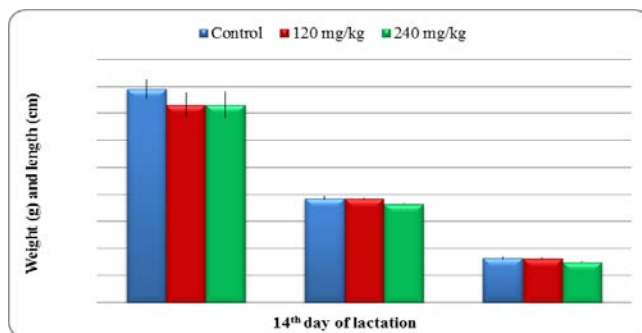


Fig. 18. A histogram showing effect of anti-osteoarthritic drug (Genuphil) on neonates body weight, length and tail length at the 14th day of lactation.

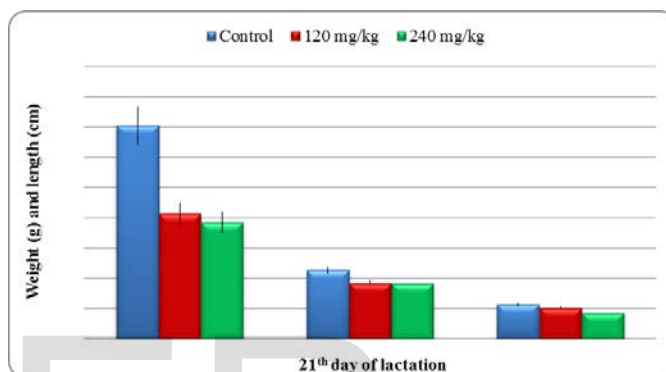


Fig. 19. A histogram showing effect of anti-osteoarthritic drug (Genuphil) on neonates body weight, length and tail length at the 21th day of lactation.

3.10 Skeletal examination

Control group

At the 7th day of lactation, the cleared cartilage and bone preparations of control rat neonates have designated that in all parts of the axial skeleton skull, vertebrae and ribs as well as appendicular skeleton comprising the fore and hind limbs, pectoral and pelvic girdles, both chondrification and ossification processes have been obviously completed. Well ossified skeletal elements were observed in skeletal system of a control neonate of rat received distilled water from 5th day of gestation to 6th day of lactation. These cases are well illustrated in Figs. (20A&21A) which are displaying the developed cartilage and bone in the different parts of skeleton of these neonates.

Treated groups

Albino rat neonates of this group maternally treated with 120 mg/kg of Genuphil from 5th day of gestation to 6th day of lactation showed some skeletal abnormalities (Fig. 20B). Shortness in the length of 13th rib and thinning in 12th rib were seen in one neonate (Fig. 21B). The major skeletal defects were observed mainly in hind limb bones. Abnormal shape of phalanges was observed in hind limb of some neonates (Fig. 20B). Absence of patella bone was seen in one neonate (Fig. 22A). Fusion of 2nd, 3rd and 4th metatarsal bones were also observed in one neonate (Fig. 22A). The beginning of fibula was connected with tibia by only a transparent soft cartilage (Fig. 22A). Abnormal location of phalanges and metatarsal bones

(diffused bones) was observed in the hind limb of one neonate (Fig. 20B). Curvature of the phalanges of the first digit was seen in the hind limb of one of the neonates (Fig. 22B). Abnormal location of the 5th metatarsal bone was also seen in the hind limb of one neonate (Fig. 22B). Shortness in the length of 13th rib was seen in one neonate maternally treated with 240 mg/kg Genuphil from 5th day of gestation to 6th day of lactation (Fig. 20C).

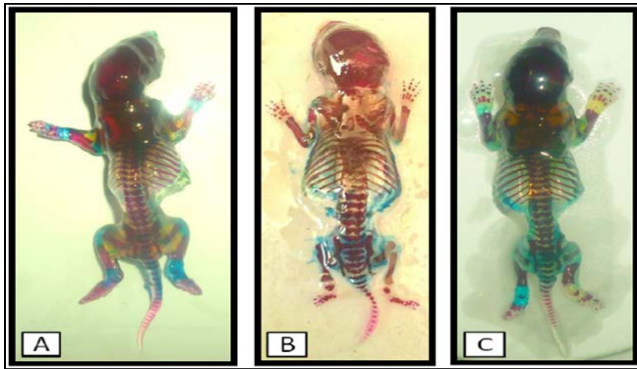


Fig. 20. Photographs of skeletal system of albino rat neonate at the 7th day of lactation and stained with Alizarin red - S and Alcian blue. A: Skeletal system of control neonate B: treated with 120 mg/kg of Genuphil. C: treated with 240 mg/kg of Genuphil.

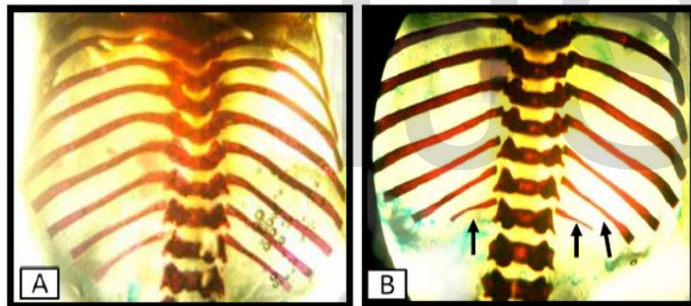


Fig. 21. Photographs of the ribs of albino rat neonate at the 7th day of lactation stained with Alizarin red - S and Alcian blue (Bones in red and cartilages in blue). A: The ribs of control neonate. B: Shortness in the length of 13th rib and thinning in 12th rib in neonate maternally treated with 120 mg/kg of Genuphil.

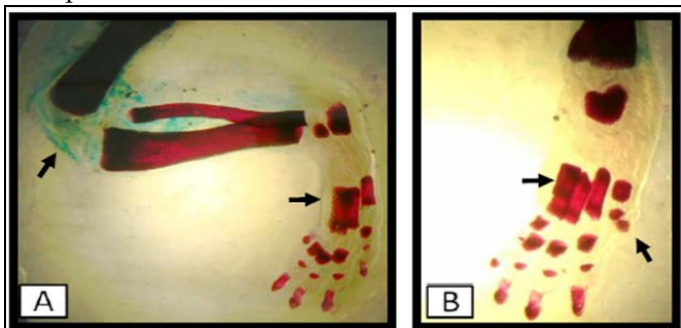


Fig. 22. Photographs of hind limb of albino rat neonate at the 7th day of lactation stained with Alizarin red - S and Alcian blue (Bones in red and cartilages in blue). A: Hind limb of albino rat neonate maternally treated with 120 mg/kg of

Genuphil. B: treated with 120 mg/kg of Genuphil.

3.11 Histopathological Findings

Group of fetuses in seven days old

The liver of control; there was no histopathological alteration and the normal histological structure of the central vein and surrounding hepatocytes were recorded in (Fig. 23A). However, in the kidney; there was no histopathological alteration and the normal histological structure of the glomeruli and tubules were recorded in (Fig. 24A).

The liver in the group administrated 120 mg/kg; the hepatocytes showed fatty change in diffuse manner (Fig. 23B). But in the Kidney; Fatty change was noticed in the lining epithelium of the tubules (Fig. 24B).

The Liver of Group administrated 240 mg/kg; the portal area showed oedema with inflammatory cells infiltration in association with dilatation in the bile ducts and congestion in the portal vein (Fig. 23C). The Kidney was swelling degeneration was detected in the lining epithelium cells of the tubules while the glomeruli showed swelling in the lining endothelium of the tufts (Fig. 24C).

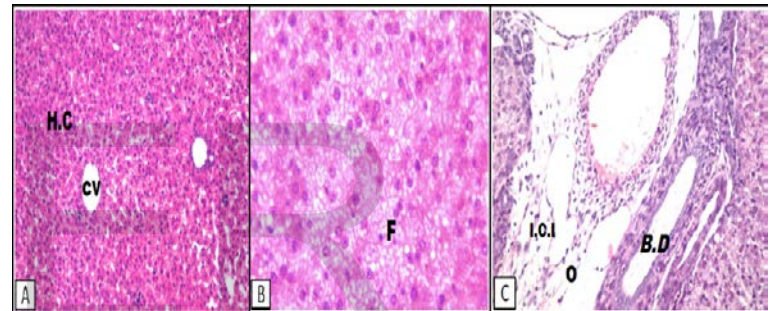


Fig. 23. Photomicrographs of a section of liver of albino rat neonates at the 7th day of lactation. A: A section of liver of control neonates H&E (x40); B: treated with 120 mg/kg of Genuphil H & E (x40); C: treated with 240 mg/kg of Genuphil H & E (x40).

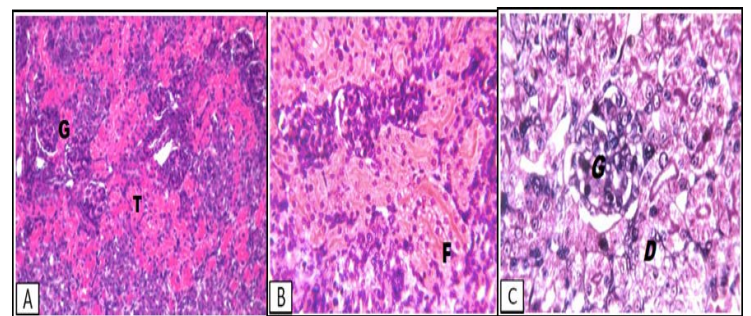


Fig. 24. Photomicrographs of a section of kidney of albino rat neonates on the 7th day of lactation. A: A section of kidney of control neonates; B: treated with 120 mg/kg of Genuphil; C: treated with 240 mg/kg of Genuphil.

Group of Fetuses in fourteen days old

Liver of control was no histopathological alteration as recorded in (Fig. 25A). However the Kidney was no histopathological alteration as recorded in (Fig. 26A).

Liver in the group administrated 120 mg/kg; Granular and swelling degenerations were detected in the hepatocytes (Fig.

25B). While, in the Kidney; there was inflammatory cells infiltration in the lumen of the tubules (Fig. 26B).

Liver of Group administrated 240 mg/kg was dilatation in the portal vein, inflammatory cells infiltration and dilatation with newly formed bile ducts in the portal area (Fig. 25C). While, in the Kidney; Focal haemorrhage was detected in between the degenerated tubules (Fig. 26C).

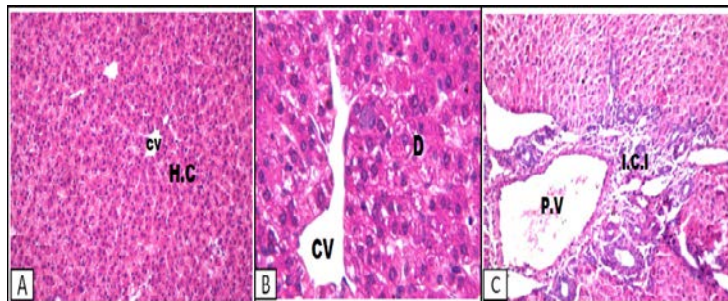


Fig. 25. Photomicrographs of a section of liver of albino rat neonates at the 14th day of lactation. A: A section of liver of control neonates H&E (x40); B: treated with 120 mg/kg of Genuphil H&E (x40); C: treated with 240 mg/kg of Genuphil H & E (x40).

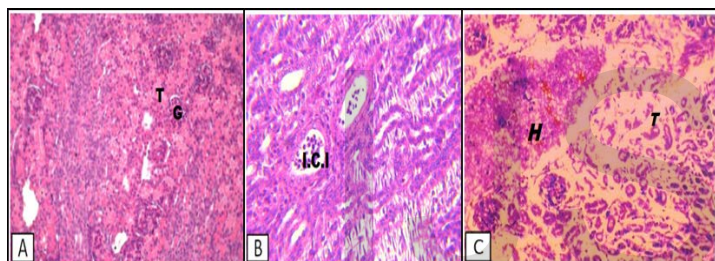


Fig. 26. Photomicrographs of a section of kidney of albino rat neonates at the 14th day of lactation. A: A section of kidney of control neonates H&E (x40); B: treated with 120 mg/kg of Genuphil H&E (x40); C: treated with 240 mg/kg of Genuphil.

Group of fetuses in twenty one day old

Liver of control was no histopathological alteration as recorded in (Fig. 27A). However, the Kidney was no histopathological alteration as recorded in (Fig. 28A).

Liver of group administrated 120 mg/kg; kuffer cells were proliferated in diffuse manner between the hepatocytes associated with dilatation in the central vein (Fig. 27B). While, the Kidney was proliferation of fibroblasts in between the obliterated tubules (Fig. 28B).

Liver in Group administrated 240 mg/kg; Focal fibrosis was detected in between the hepatocytes in association with dilatation in the portal vein (Fig. 27C). While, in the Kidney, the lining epithelium of the tubules showed swelling degeneration (Fig. 28C).

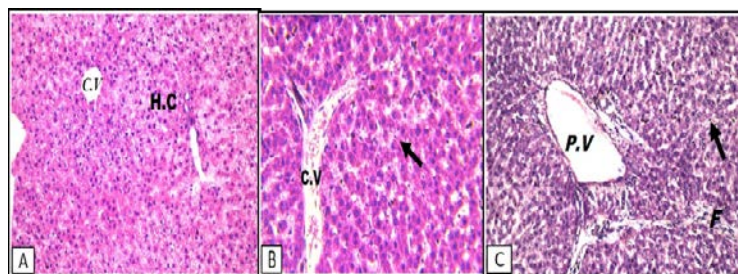


Fig. 27. Photomicrographs of a section of liver of albino rat neonates at the 21th day of lactation H&E (x40). A: A section of liver of control neonates; B: treated with 120 mg/kg of Genuphil; C: treated with 240 mg/kg of Genuphil.

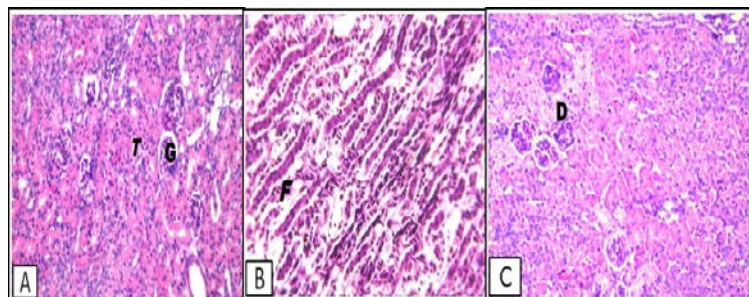


Fig. 28. Photomicrographs of a section of Kidney of albino rat neonates at the 21th day of lactation (H&E x40). A: A section of kidney of control neonates; B: treated with 120 mg/kg of Genuphil; C: treated with 240 mg/kg of Genuphil.

4 DISCUSSION

Because approximately 50% of pregnancies are unplanned (Henshaw, 1998; Han et al., 2005), women are frequently exposed to therapeutic drugs not necessarily intended to be used during pregnancy. In addition, large number of pregnant women needs continuous therapy for chronic conditions. This reality is complicated by the fact that medicines are almost never tested in pregnant women at the time they are introduced into the clinical setting. In addition, maternal conditions and environmental factors may both adversely affect the natural development of the fetus and increase maternal morbidity and mortality rates (Nava-Ocampo & Koren, 2007).

The embryo is most susceptible to drug-induced damage during the peak period of organogenesis, between 4 and 12 weeks of the first trimester. However, after the 12th week of gestation, teratogens still can affect the growth and function of organs. Because of the difficulty in studying the potential effects of medications on fetal development and growth, the teratogenic risk for more than 90% of the U.S. Food and Drug Administration (FDA)-approved medications remains unknown. Much of the evidence available is derived from observational studies, often with a relatively small number of patients (Lo & Friedman., 2002).

In order for a drug to be excreted in the breast milk, it must first be absorbed in the maternal circulation and then passed from the maternal circulation to the breast milk. The concentration of a drug in the maternal circulation is dependent upon the dose, systemic bioavailability, and distribution and clear-

ance rate of the drug (Hale, 2000). Several factors influence the movement of the drug to the breast milk. Drugs that are highly protein bound are less likely to leave the maternal circulation and be transferred into breast milk as there is a lower protein concentration in milk than in plasma, and only the free (unbound) drug can leave the maternal circulation and enter into breast milk (Hale, 2000). Lipid soluble drugs are more likely to enter the breast milk than those that are water soluble (Loebstein et al., 1997). Because breast milk has a significantly lower pH than maternal plasma, weak acids will ionize in the maternal plasma and reduce their passage into milk, and weak bases are nonionized and will, thus, reach the more acidic milk where they may be trapped. Drugs with a high molecular weight (e.g., insulin, heparin) are too large to cross the alveolar acini (the glandular tissue within which breast milk is synthesized) (Hale, 2000).

There is no information and previous studies available about the safety of Genuphil during pregnancy. Therefore, we made a further study about the effect of this medicine during pregnancy and lactation.

In our study, the teratogenicity of Geneuphil in pregnant rats was in the form of decrease of body weight gain. The decrease of body weight gain was observed after administration of 120 & 240 mg/kg BW Genuphil daily from 5th to 19th day of gestation. The average weight of placenta of pregnant rats treated with 120 & 240 mg/kg of Genuphil was also decreased as compared to the control group.

In the present study, Genuphil (120 & 240 mg/kg) caused growth retardation represented by decrease in fetal body weight, body length and tail length during gestation and lactation; these changes were dose and time dependent. Manifestations of Teratogenesis may include restricted growth, fetal demise, carcinogenesis, or malformations (Koren et al., 1998). In our study, slightly high percentage of fetal mortality including resorptions and dead fetuses was observed in Genuphil treated groups and increased after birth, particularly with high dose (240 mg/kg). Total mortality rate of fetuses maternally treated with 120 mg/kg Genuphil from 5th to 19th day of gestation was 9.42% compared to control while in the other group, total mortality rate of fetuses maternally treated with 240 mg/kg Genuphil from 5th to 19th day of gestation was 9.66%.

Our study showed that the total mortality rate of neonates maternally treated with 120 mg/kg of Genuphil from 5th day of gestation to 6th, 13th and 20th day of lactation was 9.09 % (after birth to 21th day of lactation) while the total mortality rate of neonates maternally treated with 240 mg/kg of Genuphil from 5th day of gestation to 6th, 13th and 20th day of lactation was 43.75 % (after birth to 21th day of lactation). Number of dead neonates was two at first day of lactation and four at 2nd day of lactation. This number of dead neonates occurred with dose 120 mg/kg While twenty eight dead neonates were found during lactation with dose 240 mg/kg. Twenty seven neonates died from 1st day of lactation to 4th day of lactation and one neonate was found dead at 14th day of lactation.

The effect of a medication depends on the dose that reaches the fetus. This dose is affected by the maternal dose, the distri-

bution of the drug in the maternal bloodstream, placental function, maternal and fetal genetic and physiologic status, as well as exposures to other drugs, chemicals, or environmental hazards (Yankowitz & Niebyl, 2001). Another significant factor is the gestational age at the time of exposure. The morphological changes observed in the present work proved that Genuphil caused gross malformations namely, subcutaneous hematoma in different sites, abnormal body shape, abnormalities in limbs, especially absence, shortness and contraction of fore limbs.

In our study, fetal skeletal abnormalities were observed in group of fetuses maternally treated with 120 & 240 mg/kg of Genuphil from 5th to 19th day of gestation. The abnormalities included Wavy, bent ribs and shortness in the length of 13th rib. In complete ossification of skull bones and the distal one-third of the caudal vertebrae were observed in some fetuses. The major skeletal defects were observed mainly in hind and fore limb bones in the form of Hand/forelimb abnormal shape (claw hand), Curvature of the fore limb, Incomplete ossification of the carpal bones of the fore limb and tarsal bones of the hind limb. Albino rat neonates at 7th day of lactation maternally treated with 120 & 240 mg/kg of Genuphil from 5th day of gestation to 6th day of lactation showed Shortness in the length of 13th rib and incomplete ossification in the carpal bones (carpus) of the fore limb.

In our study, histopathological examinations revealed Few inflammatory cells infiltration in the portal area as well as in between the fatty changed hepatocytes with dilatation in the portal vein in the liver of the pregnant rats treated with 120 mg/kg of Genuphil from the 5th to the 19th day of gestation while dilatation in the central vein associated with brown to yellow pigmentation in between the fatty changed hepatocytes and dilatation in the portal vein with inflammatory cells infiltration were detected in the liver of the pregnant rats treated with 240 mg/kg of Genuphil from the 5th day to the 19th day of gestation. During gestation, we found that the kidney of the pregnant rats treated with 120 mg/kg of Genuphil from 5th to 19th day of gestation showed degenerative change in the lining epithelium of the tubules at the corticomedullary while swelling in the lining epithelium of the tubules was noticed in the kidney of pregnant rats with dose 240 mg/kg BW Genuphil.

In our study, the hepatocytes of the liver of fetuses in seven days old showed fatty change in diffuse manner after oral administration of 120 mg/kg of Genuphil from 5th day of gestation to 6th day of lactation while the portal area in the liver of fetuses in seven days old showed oedema with inflammatory cells infiltration in association with dilatation in the bile ducts and congestion in the portal vein with the dose 240 mg/kg of Genuphil. Fatty change in the lining epithelium of the tubules was noticed in the kidney sections of fetuses in seven days old after oral administration of 120 mg/kg of Genuphil from 5th day of gestation to 6th day of lactation. Swelling degeneration was detected in the lining epithelium cells of the tubules while the glomeruli showed swelling in the lining endothelium of the tufts in the kidney of fetuses in seven days old with the dose 240 mg/kg of Genuphil. Granular and swelling degenerations were detected in the hepatocytes

of the liver of fetuses in fourteen days old after oral administration of 120 mg/kg of Genuphil from 5th day of gestation to 13th day of lactation while dilatation in the portal vein, inflammatory cells infiltration and dilatation with newly formed bile ducts in the portal area were noticed in the liver with the dose 240 mg/kg of Genuphil. We found that kidney of fetuses in fourteen days old showed inflammatory cells infiltration in the lumen of the tubules after oral administration of 120 mg/kg of Genuphil from 5th day of gestation to 13th day of lactation while focal haemorrhage in between the degenerated tubules was detected in the kidney of fetuses in fourteen days old with the dose 240 mg/kg of Genuphil.

In the liver sections of neonates at the 21th day of lactation, kupffer cells were proliferated in diffuse manner between the hepatocytes associated with dilatation in the central vein after oral administration of 120 mg/kg of Genuphil from 5th day of gestation to 20th day of lactation while Focal fibrosis was detected in between the hepatocytes in association with dilatation in the portal vein in the liver of neonates at the 21th day of lactation with the dose 240 mg/kg of Genuphil. Proliferation of fibroblasts in between the obliterated tubules was observed in the kidney of neonates at the 21th day of lactation after oral administration of 120 mg/kg of Genuphil from 5th day of gestation to 20th day of lactation while the lining epithelium of the tubules showed swelling degeneration in the kidney of neonates at the 21th day of lactation with the dose 240 mg/kg of Genuphil.

5 CONCLUSION

It is evident that Genuphil is teratogenic and much care must be given to prevent the increased risk if Genuphil is administered during pregnancy and lactation.

6 REFERENCES

- Brent, R. L. (1995). The application and principles of toxicology and teratology in evaluating the risks of new drugs for treatment of drug addiction in women of reproductive age, NIDA Res. Monoger. 149: 130-184.
- Banchroft, J.D., Stevens, A. & Turner, D.R. (1996). Theory and practice of histological techniques. Fourth ed. Churchill livingstone, New York, London, San Francisco, Tokyo.
- Hale, T. (2000). Medications and Mother's Milk (9th Ed.). Amarillo, TX: Pharms of Publishing.
- Han, J.Y., Nava-Ocampo, A.A. & Koren, G. (2005). Unintended pregnancies and exposure to potential human teratogens. Birth Defects Res A Clin Mol Teratol. 73:245-248.
- Henshaw, S.K. (1998). Unintended pregnancy in the United States. Fam Plann Perspect. 30(1): 24-29.
- Inouye M. (1976). Differential Staining of cartilage and bone in

fetal mouse skeleton by alcian blue and alizarin red-s. Congenital Anomales. 19: 171-173.

- Kean, W.F., Kean, R. & Buchanan, W.W. (2004). Osteoarthritis: symptoms, signs and source of pain. Inflammopharmacology. 12(1): 3-31.
- Koren, G., Pastuszak, A. & Ito, S. (1998). Drugs in pregnancy. N Engl J Med. 338(16):1128-36.
- Loebstein, R., Lalkin, A., & Koren, G. (1997). Pharmacokinetic changes during pregnancy and their clinical relevance. Clinical Pharmacokinetics. 33(5), 328-343.
- Lo, W.Y. & Friedman, J.M. (2002). Teratogenicity of recently introduced medications in human pregnancy. Obstet Gynecol. 100(3):465-73.
- McClain, R.M. & Becker, B.A. (1975). Teratogenicity, foetal toxicity and placental transfer of lead nitrate in rats. Toxicol. Appl. Pharmacol. 931: 72-82.
- Nava-Ocampo, A.A. & Koren, G. (2007). Human teratogens and evidence-based teratogen risk counseling: the Motherisk approach. Clin Obstet Gynecol. 50(1):123-31.
- Schnitaer, T.J., Burmester, G.R. & Mysler, E. (2004). Comparison of lumiracoxib with naproxen and ibuprofen in the Therapeutic Arthritis Research and Gastro-intestinal Event Trial (TARGET), reduction in ulcer complication: randomised controlled trial. Lancet, 364: 665-674.
- Snell, G.D. (1956). Biology of the laboratory Mouse, 5th Ed. The Blakiston Company, Philadelphia.
- Statistical Analyses Systems (SAS) (2009). SAS Program ver. 9.2, SAS institute incorporation, Cary, NC 27513 USA.
- Yankowitz, J., & Niebyl, J. R. (2001). Drug Therapy in Pregnancy (3rd Ed., Rev.). Philadelphia: Lippincott, Williams & Wilkins.

Author: Abdel Wahab El-Ghareeb, Department of Zoology, Faculty of Science, Cairo University- Egypt, E-mail:drelghareeb@yahoo.com

Co-Authors: Hamida Hamdi, Zoology department, Faculty of Science, Taif University, Saudi Arabia, Salwa Farouk and Esraa Khaled, Department of Zoology, Faculty of Science, Cairo University- Egypt.